

A prospective study comparing the efficacy of cyanoacrylate glue injection versus conventional fistulectomy in management of patients with fistula in ano

Shruti G. Sheelin*, Vijaya L. Patil and Surekha Rathod

Department of General Surgery, BLDEU's Shri B.M. Patil Medical College Hospital and Research Centre, Solapur Road, Vijayapur-586103, Karnataka, India

Received: 01st June 2021; Accepted: 2nd February 2022; Published: 01st April 2022

Abstract: *Background:* Management of fistula in ano is challenging and debatable. Although various surgical techniques are described but none of them are free from complications like recurrence, pain, incontinence, delayed wound healing. Cyanoacrylate glue due to its excellent tissue gluing property is being used in variety of surgeries. Hence we intend to study and compare the efficacy of Cyanoacrylate glue injection versus fistulectomy in management of patients with fistula in ano. *Material and Methods:* From October 2017 - May 2019, 60 patients with fistula in ano were enrolled in the study. 30 patients were subjected to cyanoacrylate glue injection, and 30 patients underwent fistulectomy. All patients after clinical examination were subjected for MRI fistulogram before undergoing the procedure. Patients were followed up at 1 month, 3 months and 6 months following procedure. *Results:* Success rate after single application of glue was 90%. Mean duration of the procedure was around 15 minutes. Mean pain score was 1.3, no glue associated complication was seen. None of them complained of incontinence. Mean duration of hospital stay was 1.2 days. In patients treated with fistulectomy mean pain score was seen to be 6.4, mean duration of procedure was around 38.6 minutes, two of the patients had wound infection, mean duration of hospital stay was 7.2 days. Three patients with fistulectomy presented with recurrence, none of them had incontinence. *Conclusion:* Cyanoacrylate glue injection can be used as noninvasive, cost effective, sphincter saving technique as an alternative to fistulectomy.

Keywords: Fistulectomy, Fistula in Ano, Cyanoacrylate glue.

Introduction

Fistula-in-Ano is an intriguing problem of the Ano-rectal region in general population. The patient's first visit, accurate initial surgical treatment plays an important role in healing of the fistulous tract. Fistulectomy is one of the gold standard procedure practiced since ages [1]. But this procedure is difficult in patients with high internal opening, anterior fistulas in women, patients with previous anorectal surgeries and in patients who already have disturbance of continence and in those who have pre existing risk of incontinence such as Crohn's disease, HIV and elderly [2].

Recently array of methodologies are followed in the management of fistula in ano, but none of them are free from complications such as delayed wound healing, extensive perianal wounds /scar, incontinence, recurrence [1]. Cyanoacrylate glue

injection is simple to use, cost effective, repeatable and it does not preclude future surgery if required as this procedure does not disturb sphincter architecture. Hence we intend to find out the efficacy of cyanoacrylate glue injection as compared with conventional fistulectomy in cases of fistula in ano.

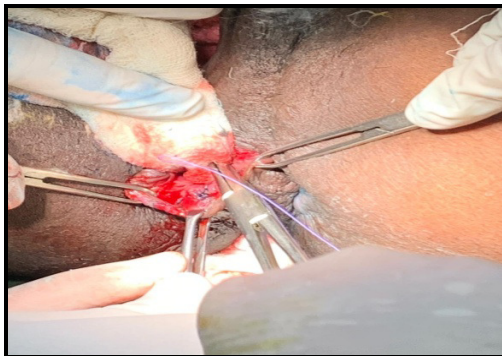
Material and Methods

60 patients with fistula in ano from October 2017 till May 2019 admitted in surgical department of BLDEU Shri B M Patil Medical College Hospital were enrolled into the study. Permission was obtained from the ethical committee for the proposed study. Informed written consent was obtained from each patient for the study. All patients were thoroughly examined clinically and subjected for MRI Fistulogram before undergoing

surgical procedure. Patients were allocated to study group (Cyanoacrylate glue injection) and control group (Fistulectomy) alternatively. Fistula associated with abscesses, crohns disease, tuberculosis, carcinoma anal canal/rectum were excluded from the study.

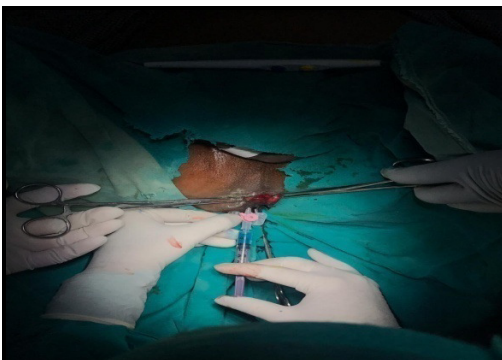
Procedure of Cyanoacrylate Glue Injection [3]: Procedure was done under regional anaesthesia with patient placed in lithotomy position. After painting and draping with antiseptic solution, about 2ml of methylene blue dye was injected from external opening with syringe nozzle into the tract and its spillage from internal opening confirmed, tract was scooped thoroughly of all granulation tissue. Hydrogen peroxide wash was given. Internal opening was ligated loosely with vicryl of 8 sutures using vicryl no 1 [Figure 1].

Fig-1: Ligation of Internal opening



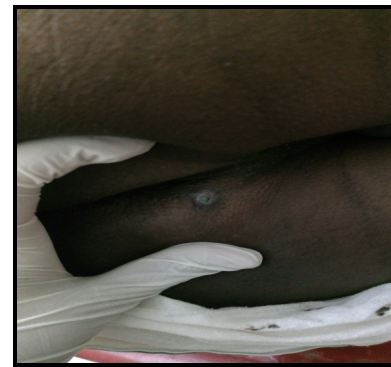Once this is done 0.5 ml of cyanoacrylate glue was loaded into 2 ml syringe under all aseptic precautions which was connected to a 5Fr infant feeding tube. Catheter tip was introduced gently into the fistula tract till internal opening is reached and glue was injected gradually [Figure 2].

Fig-2: Injection of cyanoacrylate glue through external opening



Bubbling of glue was confirmed at the internal opening, catheter was gradually withdrawn till bubbling is noted at the external opening [Figure 3]. The loosely sutured vicryl at internal opening is then tightened. This procedure does not require any dressing. The glue gets polymerized and gets stabilized within 5-10 seconds. Oral Ofloxacin and Ornidazole was prescribed daily for 1 week .Patients were asked to rate their pain score on the visual analogue scale ranging from 0 - 10. The patients were reexamined every week for the 1st month, at 3rd month and 6th month. Patients with recurrence were allocated for glue injection for second time and were followed up subsequently.

Fig-3: Post procedure image showing glue at external opening



Procedure of fistulectomy: The patients were operated under regional anesthesia. Internal opening was identified after injecting methylene blue. A probe was passed into the tract through the external opening. Fistulectomy was initiated by taking a keyhole skin incision over the fistulous tract and encircling the external opening [4]. The incision was extended through the subcutaneous tissue, and the tract excised from surrounding tissues. While the tract was being removed, attention was paid to identifying secondary tracts, if any. Hemostasis achieved. The operating time for the procedure was calculated from the start of the dye test to the beginning of dressing of the postoperative wound.

Statistical analysis used: All characteristics were summarized descriptively. For continuous variables, the summary statistics of mean± standard deviation (SD) were used.

For categorical data, the number and percentage were used in the data summaries and diagrammatic presentation. Chi-square (χ^2) test was used for association between two categorical variables. The difference of the means of analysis variables between two independent groups was tested by unpaired t test. If the p-value was < 0.05, then the results were considered to be statistically significant otherwise it was considered as not statistically significant. Data were analyzed using SPSS software v.23.0 and Microsoft office 2007.

Results

Success of the procedure was assessed by incidence of infection, mean duration of hospital stay, pain score based on visual analogue score, incontinence based on fecal incontinence scoring, operative time, recurrence at 6month follow up period and cost effectiveness of procedure. 60 patients were enrolled in the study with 42 males and 18 females. Mean age at diagnosis of fistula was 38.9 years.

Majority of the patients presented with swelling in perianal region with mean duration of 6.8 months and discharge with mean duration of 5.7months. Nineteen patients presented with recurrent fistula in ano. On radiological evaluation Intersphincteric fistula was seen to be most common type (66.7%). 52 patients had low anal fistulas. Mean duration for cyanoacrylate glue injection was 15minutes where as mean duration required for fistulectomy was 38.6 minutes. There were statistically significant difference between mean pain score with patients treated with cyanoacrylate glue injection (1.2) and those treated with fistulectomy (6.4). This can be attributed to longer duration of surgery, lot of tissue dissection and handling in fistulectomy.

Three patients treated with fistulectomy two of the patients developed wound infection which was treated with appropriate antibiotics and dressing. No complications seen associated with cyanoacrylate glue injection. Mean duration of hospital stay for patients treated with cyanoacrylate glue injection was 1.2 days. Most patients were discharged 24 after surgery. Mean duration of hospital stay for fistulectomy group was 7.2 days. Long duration of hospital stay in this group was attributed to requirement of pain relief, daily dressing and wound care. None of the

patients in either group complained of incontinence as assessed by fecal incontinence score. Twenty seven patients treated with cyanoacrylate glue injection healed with single application of glue and were symptom free till 6 month follow up time .One patient presented with recurrence at third week and rest two patients at twelve weeks following surgery.

All three patients were treated with a week course of antibiotics followed by one more setting of glue injection and were followed up subsequently. No recurrence of symptoms were seen in any of these three patients. Three of the patients treated with fistulectomy presented with recurrence of symptoms at second month and two at third month of follow up. Two patients were treated with antibiotics with remission of symptoms while one patient required fistulectomy. Procedure was found to be cost effective compared to fistulectomy procedure.

Discussion

The common pathogenesis associated with Fistula in ano is bursting open of an acute or inadequately treated abscess involving anal canal and rectum into the perianal skin. While performing Fistulectomy for Anal fistulas we put patients at varying risk of incontinence depending on the amount of external sphincter sacrificed during the procedure [5]. It also leaves a wound in perianal region to be taken care of till it heals and also puts patient into varying amount of discomfort and pain due to surgery [2].

In order to combat all these shortcomings of the conventional procedures researchers have been studying and evaluating different procedures for treatment of anal fistulas which avoid excising sphincters, less painful, early recovery and have got low recurrence. Since then a variety of procedures have been developed for treatment of anal fistulas such as use of Fibrin sealant [6], application of Biologic and synthetic fistula plugs [7-8], Endorectal advancement flaps [9-10], dermal advancement flaps [11], LIFT [12], VAAFT [13], Stem cell application [14], which are being used as alternatives to fistulectomy with different success rates. The ultimate aim

in treating any case of Fistula in ano requires efficient healing, sphincter sparing, early recovery from the surgery without complications and should have low recurrence rate. These objectives led evolution of minimally invasive approaches, one of them being use of cyanoacrylate glue in treatment of anorectal fistulae.

Ardis in 1949 for the first time discovered the chemical 'Cyanoacrylate'. It was applied in Surgery for the first time by Coover in the year 1959. Few years later researchers developed a non toxic form of cyanoacrylate known as 'N-butyl-2-cyanoacrylate, which has ability to glue even in wet environments. When cyanoacrylate comes in contact with wet surfaces it breaks down into cyanoacetate and formaldehyde which is an exothermic reaction [15]. N butyl-2-cyanoacrylate acquires excellent tissue gluing properties, promotes faster healing, and is also bacteriostatic and haemostatic [15]. It is recently being used by surgeons for varieties of surgical procedures [16]. In a study done by Barillari et al on cyanoacrylate glue injection for anal fistula done on 21 patients he obtained 90.2% cure rate at a follow up period of about 18 months [17]. Similarly Queralto et al. also studied application of cyanoacrylate glue injection in 34 patients for anal fistulas with follow up done for two years. In his study he found cure rate of about 67.78% in first month of injection [18].

Jain *et al.* managed patients with low anal fistulas by cyanoacrylate glue injection into the fistulous tract. He studied about 20 patients and followed them for six months. He obtained success rate of 85% with this procedure [3]. Meinro and Mori have applied cyanoacrylate glue to strengthen closure of internal opening during VAAFT. From May 2006 till May 2011 they operated on 136 patients using VAAFT, patients were followed up 6 months. Primary healing was achieved in 72 patients within 2 to 3 months of surgery. Cure rate at the end of one year was 87.1 % [13].

Cyanoacrylate glue is being used and has proved to be beneficial in many other surgeries in other branches [16]. Yilmaz *et al.* studied that in comminuted fractures cyanoacrylate glue

provided sufficient rigidity for bone healing and was easy to apply [19]. A study done by Sharma A *et al.* found that fibrin glue and cyanoacrylate tissue adhesive were both effective in the closure of corneal perforations up to 3 mm in diameter [20]. A neuro-endovascular study done by Wakhloo AK *et al.* found that cyanoacrylate glue infusion can be used as primary alternative or in addition to coil embolization for treatment of duralcarotico cavernous fistula [21]. Aslan G *et al.* used cyanoacrylate glue for closure of calyceal fistula following partial nephrectomy [22].

Cyanoacrylate glue injection is easy to apply, does not have a difficult learning curve, can be performed in a short interval of time, is a sphincter sparing procedure and thus definitely there is no risk of incontinence post procedure. The operative procedure is technically simple, is cost effective and repeatable, hence does not preclude second surgery if required as it will not distort perianal anatomy or muscle architecture. Post operative pain following surgery is also minimal. In these aspects Cyanoacrylate glue injection is an ideal procedure for anal fistula. According to our study success rate of Cyanoacrylate glue injection is similar to that of Fistulectomy with similar recurrence rates in both groups, and hence patients must be explained beforehand regarding possibility of recurrence of the fistula.

Conclusion

Given its safety profile, easy of application, simplicity, less postoperative pain, reduced duration of hospital stay, early recovery, low complication rate and post operative morbidity cyanoacrylate glue injection should be considered in the management of fistula in ano as an alternative to fistulectomy. Anal Fistula is a complex disease, surgeon should become familiar with various surgical procedures including Cyanoacrylate glue injection and treatment should be tailored accordingly to each patient depending on his condition and type of fistula to gain maximum benefit from surgery.

Financial Support and sponsorship: Nil

Conflicts of interest: There are no conflicts of interest.

References

1. Kee Ho Song. New Techniques for Treating an Anal Fistula. *J Korean Coloproctol.* 2012; 28(1):7-12.
2. Abcarian H. Anal Fistula, Principles and management. 1st Edition. *Springer, New York, NY.* 2014.
3. Jain SK, Kaza RC, Pahwa M, Bansal S. Role of cyanoacrylate in the management of low fistula in ano: a prospective study. *Int J Colorectal Dis.* 2008; 23(4): 355-358.
4. Jain BK, Garg KVPK, Gupta S, Mohanty D. Comparison of a Fistulectomy and a Fistulotomy with marsupialization in the management of a simple Anal Fistula: A Randomized Controlled Pilot Trial. *J Korean Soc Coloproctol.* 2012; 28(2):78-82.
5. Garrison F. An introducing to history of medicine. *Philadelphia: Saunders.* 1922; 4(3):554-556
6. Yeung JMC et al. Fibrin glue for the treatment of fistulae in ano - a method worth sticking to?. *Colorectal Dis.* 2010; 12(4):363-366.
7. Lewis R, Luniss PJ, Hammond TM. Novel biological strategies in the management of anal fistula. *Colorectal Dis.* 2012; 14(12):1445-1455.
8. Adamina M, Hoch JS, Burnstein MJ. To plug or not to plug: a cost- effectiveness analysis for complex anal fistula. *Surgery.* 2010; 147(1):72-78.
9. Jun SH, Choi GS. Anocutaneous advancement flap closure of high anal fistulas. *Br J Surg.* 1999; 86(4):490-492.
10. Nelson RL, Cintron J, Abcarian H. Dermal island-flap anoplasty for transsphincteric fistula-in-ano: assessment of treatment failures. *Dis. Colon Rectum.* 2000; 43(5):681-684.
11. Sungurtekin U, Sungurtekin H, Kabay B, Tekin K, Aytakin F, Erdem E et al. Anocutaneous V-Y advancement flap for the treatment of complex perianal fistula. *Dis Colon Rectum.* 2004; 47(12):2178-2183.
12. Rojanasakul A, Parranaarun J, Sahakirungruang C et al. Total anal sphincter saving technique for fistula-in-ano; the ligation of intersphincteric fistula tract. *J Med Assoc Thai.* 2007; 90(3):581-586.
13. Meinero P, Mori L. Video-assisted anal fistula treatment (VAAFT): a novel sphincter-saving procedure for treating complex anal fistulas. *Tech Coloproctol.* 2011; 15(4):417-422.
14. Chapel A, Bertho JM, Bensidhoum M, Fouillard L, Young RG, Frick J, Demarquay C, Cuvelier F, Mathieu E, Trompier F, Dudoignon N, Germain C, Mazurier C, Aigueperse J, Borneman J, Gorin NC, Gourmelon P, Thierry D. Mesenchymal stem cells home to injured tissues when co-infused with hematopoietic cells to treat a radiation-induced multi-organ failure syndrome. *J Gene Med.* 2003; 5:1028-1038.
15. Saska S, Gaspar AM, Hochuli-Vieira E. Adesivos à base de cianoacrilato para síntese de tecido mole [Cyanoacrylate adhesives for the synthesis of soft tissue]. *An Bras Dermatol.* 2009; 84(6):585-592.
16. Ryu SH, Moon JS, Kim I, Kim YS, Lee JH. Endoscopic injection sclerotherapy with N-butyl-2-cyanoacrylate in a patient with massive rectal variceal bleeding: a case report. *Gastrointest Endosc.* 2005; 62:632-635.
17. Barillari P, Basso L, Larcinese A, Gozzo P, Indinnimeo M. Cyanoacrylate glue in the treatment of ano-rectal fistulas. *Int J Colorectal Dis.* 2006; 21(8):791-794.
18. Queralto M, Portier G, Bonnaud G, Chotard JP, Cabarro P, Lazorthes F. Efficacy of synthetic glue treatment of high cryptoglandular fistula-in-ano. *Gastroenterol Clin Biol.* 2010; 34(8):477-482.
19. Yilmaz C, Kuyurtar F. Fixation of a talarosteocondral fracture with cyanoacrylate glue. *Arthroscopy.* 2005; 21:1009.
20. Sharma A, Kaur R, Kumar S, Gupta P, Pandav S, Patnaik B, Gupta A. Fibrin glue versus N-butyl-2-cyanoacrylate in corneal perforations. *Ophthalmology.* 2003; 110:291-298.
21. Wakhloo AK, Perlow A, Linfante I, Sandhu JS, Cameron J, Troffkin N, Schenck A, Schatz NJ, Tse DT, Lam BL. Transvenous n-butyl-cyanoacrylate infusion for complex dural carotid cavernous fistulas: technical considerations and clinical outcome. *Am J Neuroradiol.* 2005; 26: 1888-1897.
22. Aslan G, Men S, Gulcu A, Kefi A, Esen A. Percutaneous embolization of persistent urinary fistula after partial nephrectomy using N-butyl-2-cyanoacrylate. *Int J Urol.* 2005; 12: 838-841.

Cite this article as: Sheelin SG, Patil VL and Rathod S. A prospective study comparing the efficacy of cyanoacrylate glue injection versus conventional fistulectomy in management of patients with fistula in ano. *Al Ameen J Med Sci* 2022; 15(2): 181-185.

This is an open access article distributed under the terms of the Creative Commons Attribution-Non Commercial (CC BY-NC 4.0) License, which allows others to remix, adapt and build upon this work non-commercially, as long as the author is credited and the new creations are licensed under the identical terms.

*All correspondences to: Dr. Shruti G. Sheelin, Senior Resident, Department of General Surgery, BLDEU's Shri B.M. Patil Medical College Hospital and Research Centre, Solapur Road, Vijayapur-586103, Karnataka, India. E-mail: sheelinshruti@gmail.com